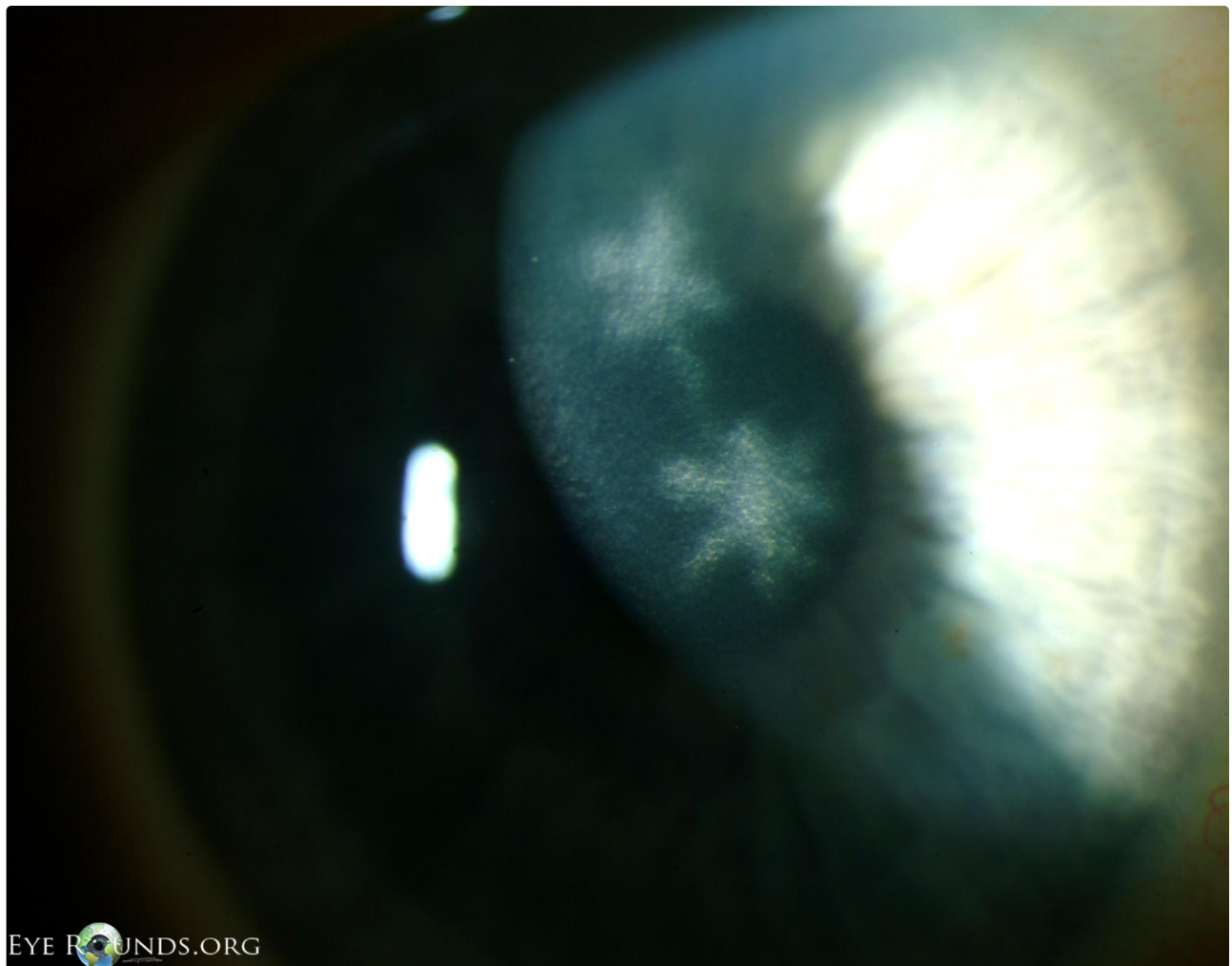


## Ghost dendrites after resolution of herpes simplex virus (HSV) epithelial keratitis

Category(ies): Cornea

Contributor: [Jesse Vislisel, MD](#)

Ghost dendrites may remain after resolution of herpes simplex virus (HSV) epithelial keratitis due to residual subepithelial infiltration and scarring in the region of the previous dendritic ulcer. To learn more about HSV keratitis, read the EyeRounds case report.



EYE ROUNDS.ORG

 Enlarge

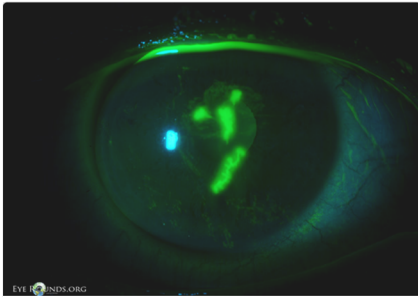
 Download

### Image Permissions:



Ophthalmic Atlas Images by [EyeRounds.org](#), [The University of Iowa](#) are licensed under a [Creative Commons Attribution-NonCommercial-ShareAlike](#)

## Related Articles



[Related Case: Herpes Simplex Keratitis](#)

## Address

University of Iowa  
Roy J. and Lucille A. Carver College  
of Medicine  
Department of Ophthalmology and  
Visual Sciences  
200 Hawkins Drive  
Iowa City, IA 52242

[Support Us](#)

## Legal

Copyright © 2019 The University of  
Iowa. All Rights Reserved  
[Report an issue with this page](#)  
[Web Privacy Policy](#) |  
[Nondiscrimination Statement](#)

## Related Links

[Cataract Surgery for Greenhorns](#)  
[EyeTransillumination](#)  
[Gonioscopy.org](#)  
[Iowa Glaucoma Curriculum](#)  
[Iowa Wet Lab](#)  
[Patient Information](#)  
[Stone Rounds](#)  
[The Best Hits Bookshelf](#)

## EyeRounds Social Media

Follow



Receive notification of new cases,  
[sign up here](#)  
[Contact Us](#)  
[Submit a Suggestion](#)